

Evaluation of Radiofrequency Thermal Ablation Results in Inferior Turbinate Hypertrophies by Magnetic Resonance Imaging

Tarik Sapci, MD; Canan Usta, MD; M. Fatih Evcimik, MD; Ziya Bozkurt, MD;
Elcin Aygun, MD; Ahmet Karavus, MD; Mustafa Peker, MD

Objectives: Nasal obstruction caused by inferior turbinate hypertrophies is one of the most frequent problems in otolaryngology. Treatment of this disease may involve medical and surgical methods. Thermal ablation with radiofrequency energy has become quite popular in the recent years as one of the surgical methods used when medical therapy is not adequate. **Study Design:** Prospective, clinical trial. **Methods:** Thermal ablation with radiofrequency energy was used in this study on the inferior turbinates of 21 patients who had nasal obstruction caused by inferior turbinate hypertrophy only. The results were evaluated subjectively by preoperative and postoperative patient- and physician-assigned visual analogue scales and objectively by magnetic resonance imaging (MRI) investigation. **Results:** By the end of the postoperative week 10, 64.76% recovery was detected according to the patient evaluation, and 40.75% recovery was detected according to the physician evaluation. Measurement of the average volumes of the inferior turbinates by MRI revealed a 8.70% postoperative reduction. The most significant change was detected in the anterior-posterior length measurement performed in the axial plane. **Conclusions:** These results suggest that thermal ablation with radiofrequency energy is an easily applied, efficient, and reliable technique in treatment of the inferior turbinate hypertrophy, and that anterior-posterior length measurement in the axial section of the inferior turbinate by MRI, which is thought as an objective evaluation method, could be an efficient diagnostic tool in detecting the efficiency of

radiofrequency on inferior turbinate. **Key Words:** Radiofrequency, magnetic resonance investigation, inferior turbinate, RFTA.

Laryngoscope, 117:623–627, 2007

INTRODUCTION

Radiofrequency thermal ablation (RFTA) is a technique in which high-frequency current passes fast through the target tissue to cause a reduction in tissue amount through ablation by heat.¹ The most important feature of RFTA is that it uses low power levels (2–10 W) and low voltage (80 V) and leads to a low degree of warming in the tissue (<100 degrees).² In RFTA application, initially, a coagulation necrosis is formed in the tissue, which is followed by tissue ablation through recovery. Today, radiofrequency is widely used in otolaryngology. Inferior turbinate, soft palate, and tongue base applications are the most popular applications. The mechanism related to the inferior turbinate applications includes submucosal fibrosis formation caused by thermal ablation, tissue hardening, and reduction in volume. In the present study, we used both subjective symptoms and measurements of turbinate volumes by magnetic resonance imaging (MRI) to objectively assess the efficacy of radiofrequency energy in treatment of nasal obstruction attributable to inferior turbinate hypertrophy.

MATERIALS AND METHODS

Study Design

A total of 21 patients (10 male and 12 female) who were referred with chronic nasal obstruction between February 2004 and September 2005 were included in this study. All patients provided written informed consent before being included in the study, which was approved by the ethics committee. All procedures were performed by one author (T.S.).

Patients

Patients with previous turbinate surgery, septal deformities, nasal polyps or tumor, nasal radiotherapy, or recurrent

From the Departments of Otorhinolaryngology–Head and Neck Surgery (T.S., C.U., M.F.E., Z.B., E.A., A.K.) and Radiology (M.P.), Fatih Sultan Mehmet Training and Research Hospital, Istanbul, Turkey.

Editor's Note: This Manuscript was accepted for publication December 1, 2006.

Send correspondence to Dr. M. Fatih Evcimik, Fatih Sultan Mehmet Training and Research Hospital, Department of Otorhinolaryngology–Head and Neck Surgery, 34752 Kadikoy, Istanbul, Turkey. E-mail: evcimik@gmail.com

DOI: 10.1097/MLG.0b013e3180306d8b

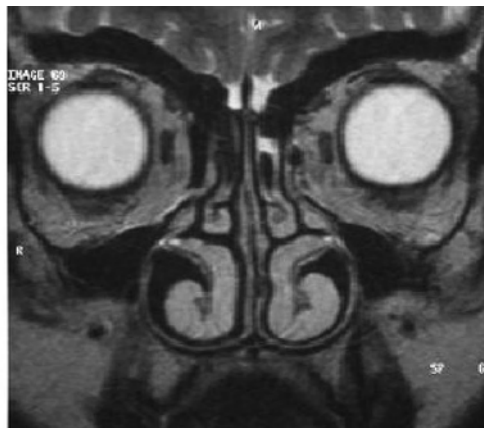
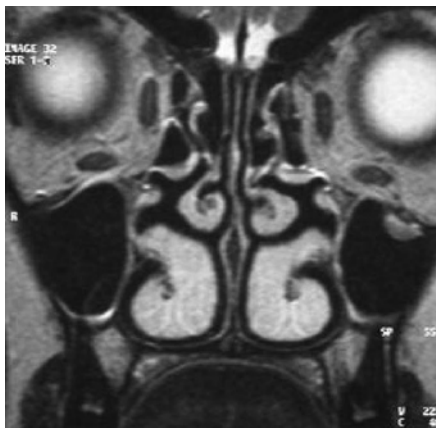


Fig. 1. Magnetic resonance image of preoperative and postoperative coronal sections.

sinusitis were excluded. Additional exclusion criteria included diabetes mellitus, oral steroid use, coagulation disorder, cardiac pacemaker, and uncontrolled hypertension. Examination included anterior rhinoscopy and nasal endoscopy in all patients. Patients had been treated previously with topical corticosteroids, antihistamines, decongestants, and topical anticholinergic agents. Patients whose complaints had subsided partially or not at all were admitted to the study. Furthermore, patients who were selected to receive surgery had smaller inferior turbinates after the nasal application of topical vasoconstrictive agents.

RFTA (Surgitron, Ellman International, Inc., Hewlett, NY) was applied on the inferior turbinate. No vasoconstrictive agent was used topically or by injection to avoid turbinate shrinkage, which was thought to increase the risk of potential mucosal injury and postoperative complications. The radiofrequency electrode was inserted submucosally under endoscopic guidance, and the energy was delivered to three different sites of each turbinate (to the anterior, middle, and posterior portions). Radiofrequency energy used in the present study was 10 to 15 W, for 15 seconds. In small turbinate, two applications were made to the anterior and posterior parts. In addition, energy delivery was stopped once whitening was established on the applied region of the mucosa (power was held constant while time was decreased). No packing was used in patients after the operation. Antibiotic therapy with amoxicillin and analgesia with acetaminophen were given for 5 days postoperatively.

Evaluation

Subjective symptoms including severity of nasal obstruction were measured by a standard 10-cm visual analogue scale (VAS).

The patient's assessment of the degree of nasal obstruction was recorded. A score of 0 represented no obstruction and no episodes of nasal obstruction, and a score of 10 indicated complete nasal obstruction and constant, unremitting nasal obstruction. Furthermore, evaluation was performed with a standard 10 cm VAS according to the size of the turbinates detected in the examination by the same physician. Postoperative evaluations were made in postoperative week 10.

Inferior turbinate volumes of all patients were calculated with paranasal sinus MRI investigation in the axial and coronal planes preoperatively and at postoperative week 10 (Figs. 1 and 2). MRI examinations were performed with patients in the supine position with Magret (Magretom Vision Plus, Siemens, Erlangen, Germany) with 1.5 Tesla (25 mT/m) power, using a standard head bandage. The examinations were performed in the axial and coronal planes. Examination sequences were T1-weighted spin echo sequence (sequence parameters: repetition time [TR], 440 ms; echo time [TE], 12 ms; section thickness, 5 mm; field of view [FOV], 193×220 ; matrix, 190×256 ; acquisition time, 1 min 44 s) and T2-weighted turbo spin echo sequence in the coronal plane (sequence parameters: TR, 5,400 ms; TE, 99 ms; section thickness, 3 mm; FOV, 193×220 ; matrix, 264×512 ; acquisition time, 2 min 15 s). Longitudinal and transverse dimensions of inferior turbinates of each case were formed over the images obtained in the sections passing through the uncinate process level in the coronal plane and by measurement of the anterior-posterior size of the turbinate in the section where the turbinate was the longest, in the axial plane. Then, turbinate volumes were calculated according to the formula, Ellipse Volume (mm^3) = longitudinal

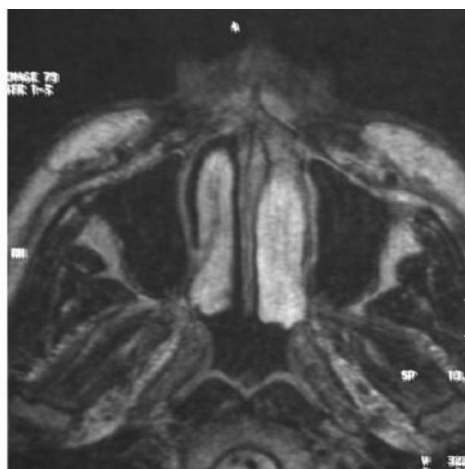
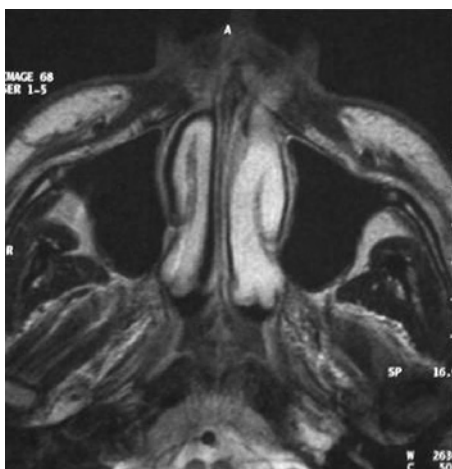

Fig. 2. Magnetic resonance image of preoperative and postoperative axial sections.

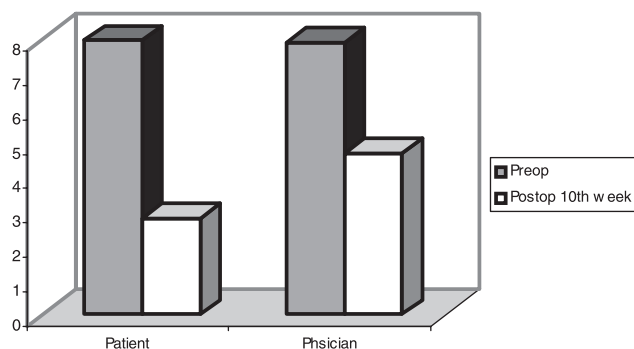


Fig. 3. Distribution of preoperative and postoperative week 10 visual analogue scale (VAS) values.

length (mm) \times transverse length (mm) \times anterior-posterior length (mm) $\times \pi/6$.

Statistical Analysis

Statistical analysis was performed by a specialized company using the statistical software package SPSS for Windows, version 10.0 (SPSS, Inc. Chicago, IL). Student's *t* test and Wilcoxon signed rank test were used, and a *P* value of less than .05 was considered to be statistically significant.

RESULTS

Twenty-one patients (11 women, 10 men) were enrolled in the present study. The ages of the patients varied between 16 and 52 years, with an average of 36.67 ± 11.51 years. None of the patients had a history of allergy. The results of skin-prick test, nasal smears, and radioallergen sorbent test for specific allergens were all negative for all the patients. All patients had a diagnosis of vasomotor dysfunction.

Subjective Change of Symptoms

A comparison of the preoperative and postoperative VAS values indicated that serious respiratory relief was

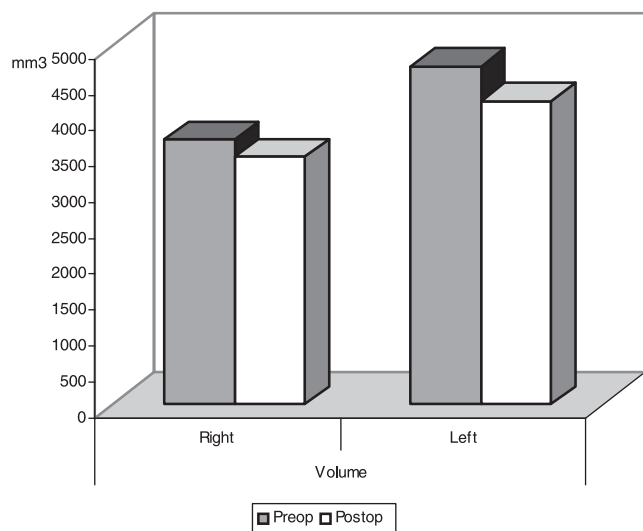


Fig. 4. Change in preoperative and postoperative inferior turbinate volumes (mm³).

TABLE I.
Comparison of Preoperative and Postoperative Inferior Turbinate Volumes (mm³).

	Volume				<i>P</i>
	Right		Left		
	Average	Standard Deviation	Average	Standard Deviation	
Preoperative	3689.05	2139.61	4713.63	2396.77	.152
Postoperative	3447.89	1882.88	4221.64	2270.43	.236
	<i>P</i> = .246		<i>P</i> = .035		

obtained in patients at postoperative week 10, which was statistically significant (*P* < .01). Furthermore, in the physician examination, a comparison of the preoperative and postoperative week 10 VAS values was also statistically significant (*P* < .01) (Fig. 3).

Objective Change of Inferior Turbinate Volume

A postoperative volume reduction was observed on comparison of the inferior turbinate volumes by preoperative and postoperative MRI. The average value of the preoperative volumes was 4201.34 ± 1999.5 mm³, whereas the average value of the postoperative volumes was 3834.7 ± 1863.0 mm³, and the reduction observed in the average value of the postoperative volumes was observed to be statistically significant compared with the preoperative average volume value (*P* = .023; *P* < .05). However, when turbinates were individually examined, although there was no statistically significant reduction in the postoperative volume of right inferior turbinate compared with the preoperative period (*P* > .05), the reduction in the left inferior turbinate volume was detected to be statistically significant (*P* < .05) (Fig. 4) (Table I). Although no statistically significant reduction was observed in the inferior turbinate volumes measured preoperatively and postoperatively in the transverse, longitudinal, and coronal sections, a statistically significant postoperative reduction was detected in the axial section (Table II) (Figs. 2, 5, and 6).

TABLE II.
Comparison of Values Obtained From Preoperative and Postoperative Coronal, Transverse, Longitudinal, and Axial Sections of Inferior Turbinate (mm).

	Preoperative		Postoperative		<i>P</i>
	Mean	Standard Deviation	Mean	Standard Deviation	
Right transverse	11,00	3,22	11,00	2,93	1.000
Left transverse	12,71	3,66	12,24	3,57	.056
Right longitudinal	14,14	4,54	13,86	4,42	.536
Left longitudinal	15,81	4,36	14,90	4,52	.100
Right axial	42,57	4,48	40,71	4,22	.001*
Left axial	42,52	4,14	41,14	4,43	.001*

**P* < .01 is statistically significant.

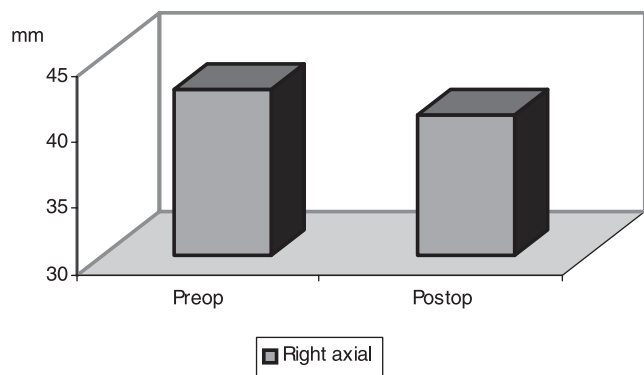


Fig. 5. Comparison of right inferior turbinate dimensions measured in axial plane (mm).

When the recovery percentages in the patient- and physician-assigned VAS and MRI results in postoperative week 10 were compared, no statistically significant difference was observed between the groups ($P > .05$). The percentage of recovery according to the patients ($64.76 \pm 16.44\%$) was statistically significant compared with the percentage of recovery observed by the physician ($40.05 \pm 18.23\%$) and detected with MRI ($8.70 \pm 16.52\%$) ($P < .01$). The percentage of recovery according to the physician was statistically significant compared with that detected by MRI ($P < .01$) (Fig. 7).

DISCUSSION

Nasal obstruction is one of the oldest and most common human complaints. External structural defects (narrow dorsum, weak alar support), internal structural defects (septal deviations, turbinate hypertrophies, nasal masses), and physiologic changes (allergic rhinitis, edema caused by hormonal irregularities, chronic sinusitis) are described as factors causing nasal air way resistance.³

Hypertrophy of the inferior turbinate is a common cause of chronic nasal obstruction. No agreement has been reached on how to deal with this problem. An ideal procedure for turbinate reduction would be associated with

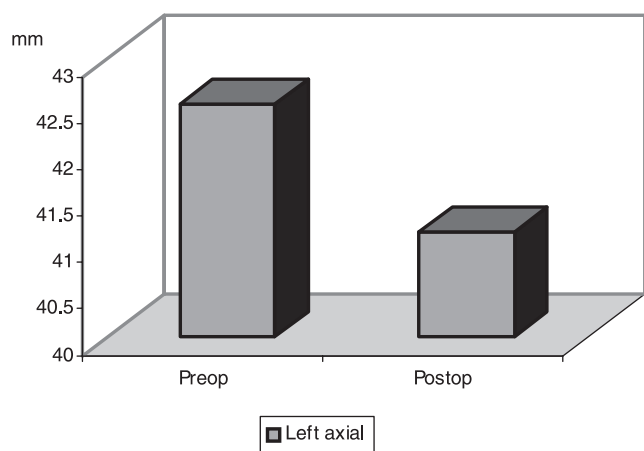


Fig. 6. Comparison of left inferior turbinate dimensions measured in axial plane (mm).

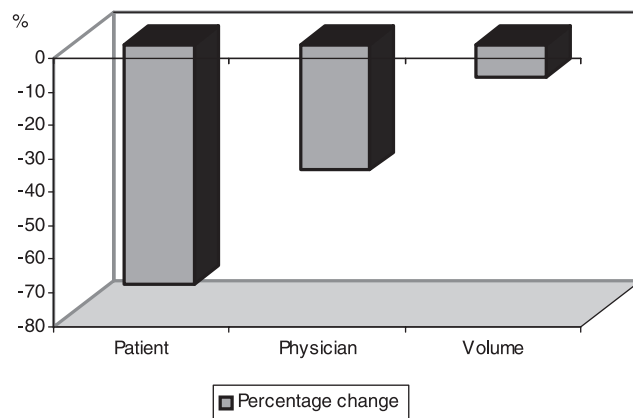


Fig. 7. Percent change graphics in patient- and physician-assigned visual analogue scale and magnetic resonance image volume groups.

minimal discomfort or adverse reactions and should preserve the physiologic function of the turbinate, such as regulating the humidification and temperature of the inspired air.¹ All of the techniques have potential complications that fall into several categories.⁴ The main goal of turbinate surgery should be the preservation of mucosal surfaces with reduction of the submucosal tissue. No technique is perfect, and each is associated with known short- and long-term complications such as bleeding and atrophic rhinitis. The variety of surgical techniques available indicates the lack of consensus on the optimal technique.

Radiofrequency tissue reduction is a surgical procedure that uses radiofrequency heating to induce submucosal tissue destruction, leading to the reduction of tissue volume.¹ This energy induces ion agitation within the tissue, which increases the local temperature and causes a thermal lesion that should occur in the deep mucosa without damaging the surface. The healing process secondarily induces fibrosis with wound contraction, leading to tissue volume reduction.

The use of radiofrequency energy for volumetric soft tissue reduction was first described by Powell et al.⁵ Therefore, radiofrequency could be useful for turbinate volume reduction because, theoretically, it should help to treat nasal obstruction without the disadvantages of the other techniques.⁶ Recently, radiofrequency energy has been used for the treatment of the hypertrophied turbinate.^{7,8,9} In studies on RFTA of the turbinate, improvement of severity and frequency of nasal obstruction were reported in 81% to 100% of cases.^{1,8} The literature points to techniques such as VAS, rhinomanometry, and acoustic rhinometry, whereas no radiologic techniques are used.^{7,10,11} Thus, we performed volume measurements with MRI examination before and after the operation to display the changes in the inferior turbinate volumes after RFTA. Although MRI examination technique has a limited use in rhinology because of the negativities in imaging of the bone structures, it is a very significant diagnostic tool in imaging of the nasal mucosal structures.⁶ There are studies reported in the literature on nasal mucosa in which an MRI technique is used in rhinology. Webber et

al.¹² have worked on demonstration of the erectile tissue in the nasal mucosa in dogs by MRI. Kennedy et al.¹³ have shown nasal physiologic changes by MRI. Saunders et al.,¹⁴ on the other hand, have investigated nose obstruction symptoms in patients having a cranial MRI examination because of other complaints. The investigators measured the nasal passage volume in the section passing through the anterior end of the middle turbinate, horizontal length of the lower turbinate, and the maximum septal mucosal thickness. They generally could not find a relation between subjective nasal obstruction and values measured by nasal MRI, yet have shown that there could be a relation in the cases where maxillary sinus mucosa was more than 5 mm thick.

In this study, clinical results of the RFA therapy were evaluated by the patient and the physician separately by VAS, which has been accepted as the most effective; however, a subjective evaluation method was used in previous studies.^{8,11} Maxwell et al.¹⁵ evaluated VAS as an easily applicable, sensitive method that could reliably display the changes in the subjective measurements. In our study, although the preoperation patient-assigned VAS average was 8.00, the physician evaluation average was 7.95. There was no statistically significant difference between preoperation patient and physician-assigned VAS evaluations. Patient VAS average in postoperative week 10 decreased to 2.81, and physician evaluation average decreased to 4.71. Smith et al.⁷ showed that 90% of the reduction in the turbinate occurred in the first 21 days, that 100% of the reduction took place at the end of week 8, and that there was no statistically significant difference between the evaluation at the end of week 8 and at the end of 1 year. It is stated in the literature that reduction starts at postoperation week 3, that the change reaches maximum at the end of week 8, and that this rate is the same as the change at the end of year 1.^{7,8}

In our study, detailed MH investigation was performed in all the cases in addition to subjective evaluation before and after the operation to measure objectively the inferior turbinate volumes. To prevent the physiological nasal cycle from causing false measurements during MR imaging, patients received nasal examination before preoperative and postoperative MR imaging to assure that nasal cycles were (pre- and postoperatively) the same. Sections were taken in MH in the axial and coronal planes. Longitudinal and transverse dimensions of inferior turbinates in each case were formed over the images obtained in the sections passing through the uncinate process level in the coronal plane and by measurement of the anterior-posterior size of the turbinate in the section where the turbinate was the longest, in the axial plane. After this, turbinate volumes were calculated according to the formula measuring ellipsoid volume, which was the most suitable formula for volume calculation. In all three sections of both turbinate volumes (longitudinal, transverse and axial), postoperation reduction was detected, but a statistically significant reduction was observed only in anterior-posterior lengths of both turbinates measured in the axial plane. This reveals that axial plane might be used for detection of the amount of reduction after operation.

As a consequence, after the RFA application, 64.76% recovery was observed in patient evaluation, 40.73% recovery was observed in physician evaluation, and 8.70% recovery was detected in MH evaluation. Although there was a significant relief in patients clinically, the fact that the change in volume detected in MH was small suggested that even very little changes in the inferior turbinate volume provided significant relief in respiration. Indeed, Smith et al.,⁷ in their study in which they performed applications at only one point in the anterior regions of the turbinates, showed that even small scale changes in the turbinates provided improvement in the symptoms through increasing of airflow in the nasal valve.

CONCLUSION

RFA is an efficient, easily applicable technique which does not lead to serious complications in the treatment of the nasal obstruction caused by inferior turbinate hypertrophies. MH and volume measurement, which we used in objective evaluation of the results, have also shown the efficiency of RFA in reduction of the inferior turbinates.

BIBLIOGRAPHY

1. Li KK, Powell NB, Riley RW, et al. Radiofrequency volumetric tissue reduction for treatment of turbinate hypertrophy: a pilot study. *Otolaryngol Head Neck Surg* 1998;119:50-573.
2. Pinczower EF, Gates GA. *Current Therapy in Otolaryngology Head Neck Surgery*. Washington: Mosby-Year Book; 1998:485-490.
3. Chang CW, Ries WR. Surgical treatment of the inferior turbinate: new techniques. *Curr Opin Otolaryngol Head Neck Surg* 2004;12:53-57.
4. Daws PJ. The early complications of inferior turbinectomy. *J Laryngol Otol* 1987;101:116-1139.
5. Powell NB, Riley RW, Troel RJ, et al. Radiofrequency volumetric tissue reduction of the palate in subjects with sleep-disordered breathing. *Chest* 1998;113:1163-1174.
6. Ng BA, Ramsey RG, Corey JP. The distribution of nasal erectile mucosa as visualized by magnetic resonance imaging. *Ear Nose Throat J* 1999;78:159163-166.
7. Smith TL, Correa AJ, Kuo T, Reinisch L. Radiofrequency tissue ablation of the inferior turbinate using a thermocouple feedback electrode. *Laryngoscope* 1999;109:176-1765.
8. Utley DS, Goode RL, Hakim I. Radiofrequency energy tissue ablation for the treatment of nasal obstruction secondary to turbinate hypertrophy. *Laryngoscope* 1999;109:683686.
9. Elwany S, Gaimae R, Fattah HA. Radiofrequency bipolar submucosal diathermy of the inferior turbinates. *Am J Rhinol* 1999;13:145-149.
10. Sapci T, Sahin B, Karavus A, Akbulut UG. Comparison of the effects of radiofrequency tissue ablation, CO2 laser ablation, and partial turbinectomy application on nasal mucociliary functions. *Laryngoscope* 2003;113:54-519.
11. Bozkurt Z, Sapci T, Sahin B, Akbulut UG. Results of radiofrequency tissue ablation. *Kulak Burun Bogaz Ihtis Derg* 2002;9:3-36.
12. Webber RL, Jeffcoat MK, Harnan JT, Ruttiman UE. MR demonstration of the nasal cycle in the beagle dog. *J Comput Assist Tomogr* 1987;11:86-871.
13. Kennedy DW, Zinreich SJ, Shaalan H, et al. Physiologic mucosal changes within the nose and ethmoid sinus: imaging of the nasal cycle by MRI. *Laryngoscope* 1988;98:92-933.
14. Saunders MW, Jones NS, Kabata JE. Parameters of nasal airway anatomy on magnetic resonance imaging correlate poorly with subjective symptoms of nasal patency. *Clin Otolaryngol Allied Sci* 1999;24:431434.
15. Maxwell C. Sensitivity and accuracy of the visual analogue scale: a psycho-physical classroom experiment. *Br J Clin Pharmacol* 1978;6:15-24.

LIT-70-04