

This feature will emphasize innovative and better ways to perform dermatologic surgery procedures. This article should be based on evidence-based literature, but may describe the author's experience with a particular procedure without being a typical clinical research article. The editors will be glad to consider ideas for topics. Any author who is considering writing an article should submit the title to our website: <http://ds.manuscriptcentral.com>.

Excision of Rhinophyma With High-Frequency Electrosurgery

MARK AFERZON, MD AND BRAD MILLMAN, MD

Department of Otolaryngology-Head and Neck Surgery, Geisinger Medical Center, Danville, Pennsylvania

BACKGROUND. Rhinophyma is an uncommon progressive disfiguring process of the lower nasal region that most commonly affects middle-aged white men. It is characterized by painless hyperplasia of the sebaceous and subcutaneous tissues, in the end stage, resulting in a bulbous nodular telangiectatic nose. Surgical modalities of treatment include electrosurgery, laser ablation, dermabrasion, cryosurgery, scalpel excision, and others.

OBJECTIVE. We present two patients with rhinophyma who were treated with the Ellman Surgitron using high-frequency current.

METHODS. Two patients with significant rhinophyma and associated subcutaneous abscesses underwent excision with the Ellman Surgitron using high-frequency electrosurgery with a

wire loop. The sebaceous hypertrophy was shaved down to the level of the normal skin surface.

RESULTS. This technique provided a quick, efficient, bloodless operative field with a good cosmetic result and pain-free post-operative recovery. Photographs were taken at regular intervals to document the healing process.

CONCLUSION. The Ellman Surgitron uses high-frequency current to achieve a bloodless field in the treatment of rhinophyma. This enabled efficient and quick removal of hypertrophied tissue with a good cosmetic result and an essentially pain-free recovery. This radiofrequency device is well suited for the outpatient setting and offers advantages over the other modalities used to treat rhinophyma.

M. AFERZON, MD AND B. MILLMAN, MD HAVE INDICATED NO SIGNIFICANT INTEREST WITH COMMERCIAL SUPPORTERS.

RHINOPHYMA IS AN uncommon progressive disfiguring condition of the nasal region that most commonly affects white men. Clinically the lower two-thirds of the nose becomes enlarged and hypervascular, developing a reddish-purple discoloration and a lobular, nodular appearance. Histologic features include a chronic inflammatory process with hypertrophy of the subcutaneous and sebaceous tissues with dilated ducts occluded with inspissated debris, bacteria, and sebum. It is believed that rhinophyma represents the end stage of acne rosacea, and may be affected by alcohol, caffeine, spicy foods, and other vasoactive influences such as climate. Patients with rhinophyma may seek medical attention due to nasal airway compromise or cosmetic deformity.^{1,2}

Medical therapy may be an option for very early

rhinophyma before scarring and fibrosis have occurred. Isotretinoin has shown some benefit in the early rhinophymatous state of rosacea. Oral antibiotics (including tetracycline, erythromycin, ampicillin, and metronidazole) have been useful in eliminating prominent pustules. The use of topical metronidazole may be another medical option in the treatment of very early rhinophyma.¹

Even though medical therapy may be useful in early rhinophyma, surgical modalities are the accepted treatment of established rhinophyma. Multiple surgical approaches have been used to treat rhinophyma, including dermabrasion, scalpel excision, electrosurgery, Shaw knife, laser, harmonic scalpel, cryosurgery, and others.^{2,3} The literature is replete with controversy regarding the best method of surgical therapy. It is generally accepted that there is greater heat dispersion with electrosurgery as compared to CO₂ laser. The depth of tissue destruction beyond the operative field approaches 1 mm with the Bovie cutting current at a power setting of 20–30 W versus a 0.5 mm depth with

Address correspondence and reprint requests to: Mark Aferzon, MD, Department of Otolaryngology-Head and Neck Surgery, Geisinger Medical Center, 100 North Academy Ave., Danville, PA 17822, or e-mail: aferzon@hotmail.com.

CO₂ laser.^{4,5} It is also generally accepted that CO₂ laser is a slower technique than electrosurgery. According to Greenbaum et al.'s⁶ study of rhinophyma, laser surgery took twice as long as electrosurgery. Regardless of the modality used, removal of tissue below the depths of the pilosebaceous unit will result in a smooth atrophic scar rather than the normal porous nasal skin. The areas at greatest risk are the thin nasal ala and the supratip area.⁷

In the literature, the terms electrosurgery, electrocautery, radiosurgery, diathermy, endothermy, and radiofrequency heating have been used interchangeably. There is a difference, however, in that *electrosurgery* uses radiofrequency electricity to generate heat in the tissue itself as compared to *electrocautery*, which is the application of heat from an outside source (as in "hot iron" cautery). Since radio waves fall between 0.01 and 300 MHz, and electrosurgical devices deliver electricity between 0.1 and 4 MHz, these devices deliver *radiofrequency* electricity.⁸ The electrosurgical device produces an alternating current of electrons at a frequency that does not stimulate muscle activity. The base frequency is sinusoidal and can be modulated or dampened to get several types of waveforms. The *cut* mode is the continuous sinusoidal waveform output of the base frequency of the generator. A thin blade electrode used in this mode leaves a smooth-edged incision similar to a scalpel blade. A *coag* output (also called damped waveform) consists of short bursts of energy with high amplitude and gaps between bursts that result in intermittent heating and a coagulum of denatured proteins. A *blended* or mixed current combines characteristics of the continuous sine wave with those of the damped sine wave to cut tissue and coagulate small bleeding vessels simultaneously.^{9,10}

Patients and Methods

Patient 1 is an 80-year-old man who presented with a 6-month history of increasing swelling of his nose, most notably of the right alar region. He was able to squeeze the area to obtain a cheesy-type material and cores. He had previously seen a dermatologist and had been treated with doxycycline and Metrogel (Galderma Laboratories, Fort Worth, TX). Following the antibiotic treatment, the inflammation and soreness resolved, however, the nasal growth continued. The patient denied nasal airway obstruction but noted that his snoring had become louder. Physical examination revealed diffuse hypertrophy of the sebaceous and subcutaneous tissue of the nose (Figure 1).

Patient 2 is a 74-year-old man who presented with a 5-year history of progressive hypertrophy of his nose. Despite appropriate antibiotic therapy, the patient developed a disfiguring rhinophyma and complained of nasal obstruction and a foul odor from his nose. Physical examination revealed significant nasal sebaceous hypertrophy and skin abscesses. Purulent and keratinous material could easily be expressed

from the nose. The anterior portion of the nose was overgrown and pedunculated to such a degree as to sag down and occlude the nasal passages bilaterally (Figure 2).

With the patient under general anesthesia, the facial area was prepped with pHisoHex (Sanofi-Winthrop Pharmaceu-

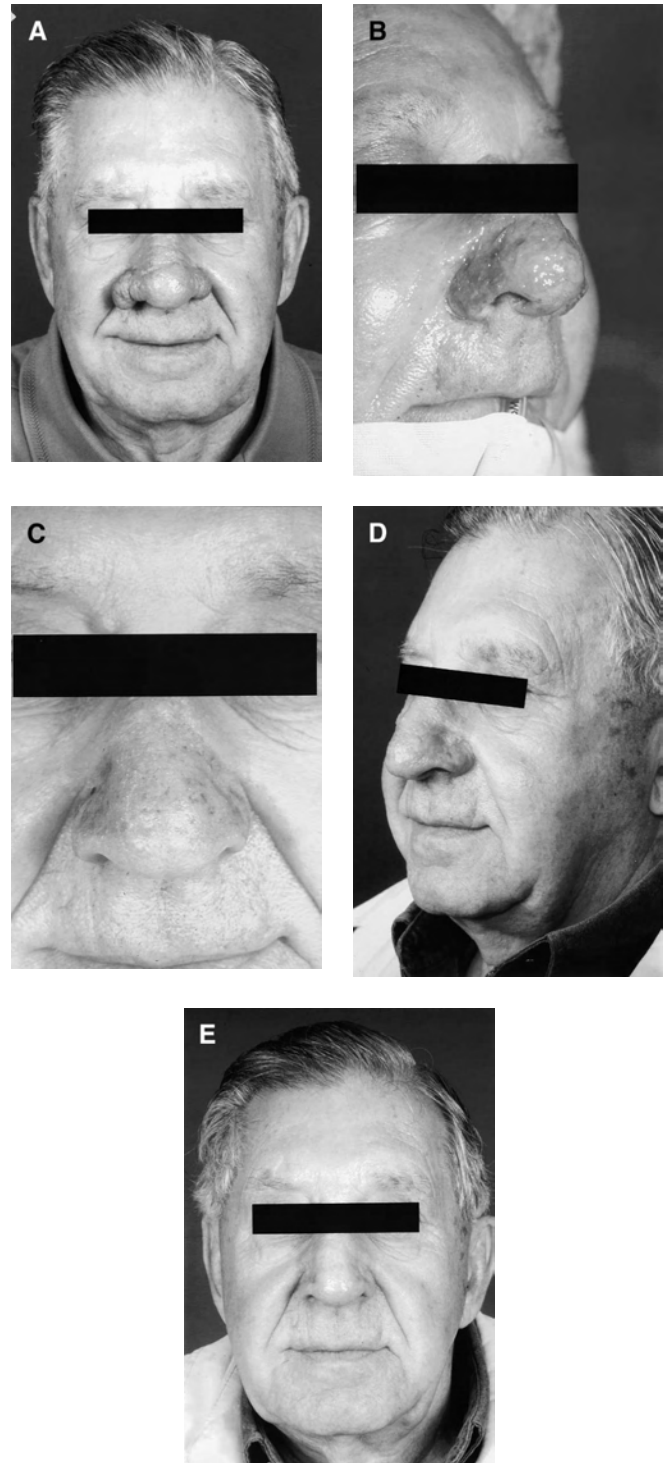


Figure 1. Patient 1 A) preoperatively, B) intraoperatively, C) 1 week after surgery, D) 4 weeks after surgery, and E) 11 weeks after surgery.

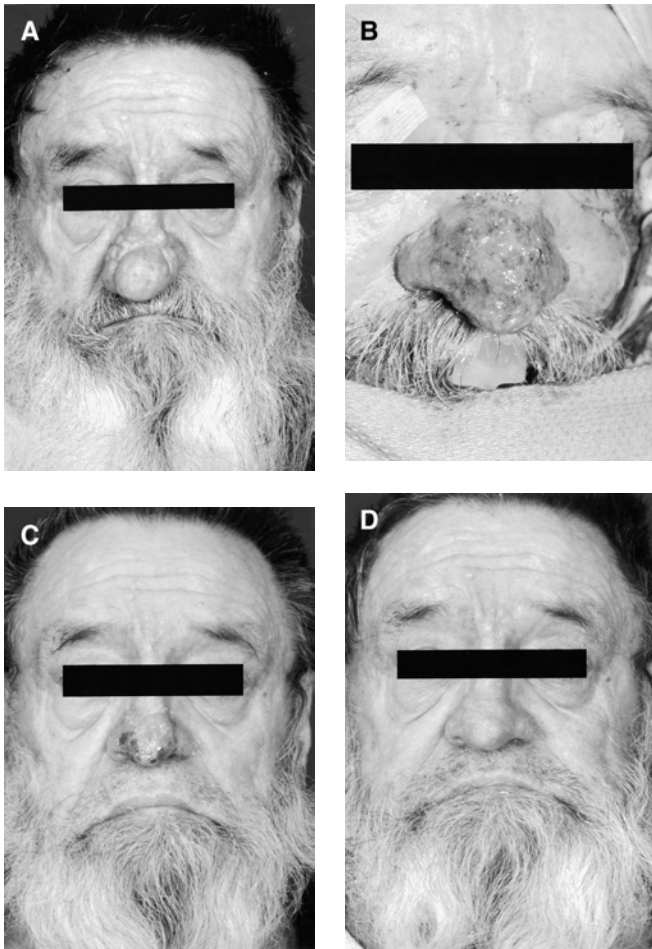


Figure 2. Patient 2 A) preoperatively, B) intraoperatively, C) 2 weeks after surgery, and D) 4 weeks after surgery.

tics, New York, NY) and draped in sterile fashion. The procedure may be performed under local anesthesia with or without sedation, but our preference is for general anesthesia. The Ellman Surgitron was used with a large wire loop. At first the blended waveform ("fully rectified") was selected and the power control dial was set between 4 and 5. Hypertrophied nasal tissue was debulked down to the level of normal-appearing skin, being careful to preserve the pilosebaceous unit. Gauze pads were used to keep the operative field dry, and a vacuum evacuator was used to suction the plume. This provided a relatively bloodless field with superb visualization of the level of excision. After the redundant tissue had been debulked and excised to the proper nasal contour, the waveform was changed to the coagulation mode ("partially rectified") and bleeding sites were cauterized. Excellent hemostasis was achieved and the area was covered with petroleum jelly. The patient received intraoperative antibiotics. The entire procedure lasted 40 minutes for patient 1 and 60 minutes for patient 2 (dependent on the amount of redundant tissue to excise).

Postoperative wound care included the application of a thin layer of petroleum jelly throughout the day as an emollient to prevent desiccation. As the patient is treated with an

oral antibiotic (cephalexin 500 mg four times a day for 7 days), an antibacterial ointment is not necessary (the possibility of contact dermatitis or topical drug sensitivity is also eliminated). Dry dressings were not used, as they may prolong crusting and erythema, and are uncomfortable for the patient. Both patients were essentially pain-free throughout the postoperative recovery period, requiring no analgesics. Reepithelialization occurred at approximately 2 weeks and no significant crusting or scarring was noted (see Figures 1 and 2).

Discussion

The atraumatic nature of high-frequency electrosurgery results from heat generated by the resistance the tissues offer to the passage of a radiofrequency wave, resulting in cutting without pressure. Tissue damage occurs as heat is allowed to accumulate in the tissue. Accumulation of lateral heat depends upon electrode contact time, power setting, electrode size, waveform, and frequency. In terms of electrode contact time, the slower the passage of the electrode, the greater the lateral heat. The proper setting of power intensity is for the electrode to pass through the tissues without sparking and without resistance. There is accumulation of lateral heat if power intensity is too high (due to sparking) or too low (due to drag). In terms of electrode size, the larger the electrode, the more lateral heat is produced and the higher the power setting necessary to operate it. In terms of the waveform, cutting mode (fully filtered) gives off the least lateral heat, and coag mode (partially rectified) gives off the most (with fully rectified in between). According to studies, the higher the frequency, the less lateral heat produced. According to the study by Maness et al.,¹¹ a frequency setting of 4 MHz was associated with the least amount of tissue injury to hamster tongue when compared to 1.7 and 2.8 MHz. These results are analogous to those expected in human skin. As the Ellman Surgitron has a frequency output of 3.8–4 MHz, this is ideal for atraumatic electrosection with minimal lateral heat and tissue damage.¹²

In our experience, the surgical treatment of rhinophyma with high-frequency electrosurgery was quick, efficient, and low in cost. Postoperative recovery was essentially pain-free, with quick tissue reepithelialization and a good cosmetic result. Wound care consisted of frequent application of petroleum jelly as an emollient. In addition to these advantages, the Ellman Surgitron is lightweight and easily portable, thus making it ideal for the treatment of rhinophyma in an outpatient setting.

References

1. Nelson B, Fuciarelli K. Surgical management of rhinophyma. *Cutis* 1998;61:313–6.

2. Hoasjoe DK, Stucker FJ. Rhinophyma: review of pathophysiology and treatment. *J Otolaryngol* 1995;24:51–6.
3. Dufresne RG, Zienowicz RJ, Rozelle A, et al. An introduction of the ultrasonic scalpel: utility in the treatment of rhinophyma. *Plast Reconstr Surg* 1996;98:160–62.
4. Clark DP, Hanke CW. Electrosurgical treatment of rhinophyma. *J Am Acad Dermatol* 1990;22:831–7.
5. Lloyd KM. Surgical correction of rhinophyma. *Arch Dermatol* 1990;126:721–3.
6. Greenbaum SS, Krull EA, Watnick K. Comparison of CO₂ laser and electrosurgery in the treatment of rhinophyma. *J Am Acad Dermatol* 1988;18:363–8.
7. Gjuric M, Rettinger G. Comparison of carbon dioxide laser and electrosurgery in the treatment of rhinophyma. *Rhinology* 1993;31:37–9.
8. Zinder DJ. Common myths about electrosurgery. *Otolaryngol Head Neck Surg* 2000;123:450–55.
9. Harrington DP. Electrosurgery fact and fiction. *Biomed Instrum Technol* 1994;28:331–3.
10. Sajjadian A, Isaacson G. Electrosurgery in the head and neck. *Ann Otol Rhinol Laryngol* 1998;107:254–60.
11. Maness WL, Roeber FW, Clark RE, et al. Histological evaluation of electrosurgery with varying frequency and waveform. *J Prosthet Dent* 1978;40:304–8.
12. Ellman International. Ellman Surgitron FFPF operating manual. Hewlett, NY: Ellman International, 1995.