

# OCULAR SURGERY NEWS®

The voice of 65,000 ophthalmologists worldwide™

Vol. 21, No. 19 • October 1, 2003

## Radiosurgery facilitates Hughes procedure for lower eyelid reconstruction

A minimal amount of bleeding is one of the advantages of this technique.

by Jay Justin Older, MD

Special to OCULAR SURGERY NEWS

**R**adiosurgery is a method in which high-frequency electrical waves cut tissue and create hemostasis at the same time. The modified Hughes procedure is a technique for eyelid reconstruction that uses a tarsoconjunctival flap from the upper lid to partially fill a defect in the lower lid. A skin graft is often used to cover the flap to form a skin surface. One of the advantages of radiosurgery is that the tarsoconjunctival flap can be created with minimal bleeding. The skin graft can also be harvested in a very dry field.

### Technique

The technique can be used for tumors measuring from 5 mm to 25 mm along the lower lid margin. Combinations of electrodes and waveforms must be chosen to achieve the desired effects.

For tumors that are on the lid margin but do not invade deeply into the palpebral conjunctiva, the lower lid tarsus can be divided horizontally for the length of the tumor (Figure 1). The lower 1 mm to 2 mm of the tarsus can

be preserved. A thin A-10 needle on a cutting setting is passed horizontally through the tarsus about 2 mm below the lid margin.

An A-10 on the cut setting of the Ellman Surgitron (Ellman International Inc., Oceanside, NY) the unit that I use for all of my procedures, gives off little lateral heat. This means the specimen is

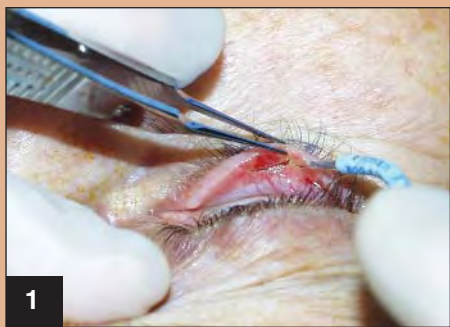*"One of the advantages of radiosurgery is that the tarsoconjunctival flap can be created with minimal bleeding."*

— Jay Justin Older, MD

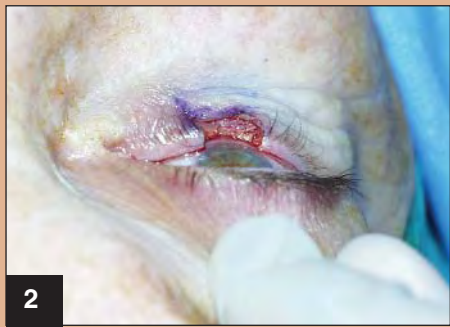usually relatively free of heat artifact at the edges, and the pathologist can give an accurate evaluation of the margin for frozen section control. The electrode passes through the tarsus with very minimal resistance. Because there is so little lateral heat, the entire specimen can be taken in this manner for frozen section analysis (Figure 2).

Another advantage of this method is the creation of the tarsoconjunctival flap. Since there is 1 mm to 2 mm of tarsus remaining in the lower lid, the height of the upper lid tarsus in the flap should be no more than 2 mm to 3 mm. An A-8 electrode, which is a bit larger in diameter than an A-10, is used on the cut/coag or hemo setting. This gives more lateral heat but better coagulation of the wound edges so, essentially, there is no bleeding (Figure 3).

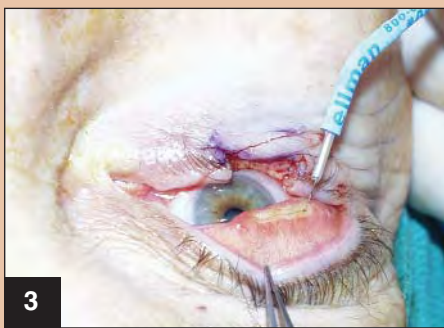
Once the tarsus is divided, Muller's muscle and the levator aponeurosis are dissected from the underlying conjunctiva until the tarsus can lie in the defect with no upward tension when the eye is closed. This might require dissection to the superior cul-de-sac. Care must be taken not to interrupt the suspensory ligament of the conjunctiva, which is in the superior cul-de-sac. I attach the tarsus of the flap to the remaining tarsus in the lower lid with 5-0 chromic sutures on a spatula needle.



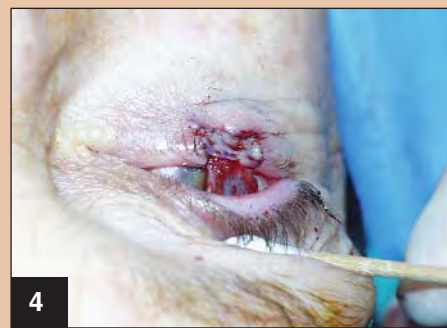**1** Horizontal incision through the lower two-thirds of the tarsus



**2** Defect remaining after all tumor is removed



**3** Incision through the upper tarsus to begin the transconjunctival flap.



**4** Tarsoconjunctival flap with skin graft in place.

### Skin graft

Using radio waves is also helpful when taking the skin graft from behind the ear (my usual choice of donor skin). I use an A-8 needle on the cut/coag setting for the skin incision so that I get some hemostasis but not enough to impede wound healing. To remove the skin from the underlying tissue, I switch to an Empire Needle (it is cone shaped and has a wider diameter to give better coagulation) on the hemo setting. I can often remove the skin graft with minimal bleeding. The ear defect is closed with interrupted, buried 4-0 Vicryl suture.

The graft is trimmed of all subcutaneous fat and cut to fit the lower lid defect. It is sewn to the recipient bed

with 7-0 chromic sutures. I use multiple sutures in the center of the graft to keep it attached to the underlying tissue since I do not use a bolster. Antibiotic drops and ointments are used to prevent infection, which can cause loss of the flap. I usually open the flap in 3 weeks (Figure 4). Patients can assume normal activities once the flap is opened.

### For Your Information:

**Jay Justin Older, MD**, is an affiliate professor of ophthalmology, University of South Florida College of Medicine. He can be reached at 4444 E. Fletcher Ave., Suite D, Tampa, FL 33613; (813) 971-3846; fax: (813) 977-2611. Dr. Older receives honoraria and expenses from Ellman International for certain educational activities.

■ Preceptorships in oculoplastic radiosurgery are available with Dr. Older. For information, call Susan at (813) 971-3846.

## High-Frequency Radiosurgery

A Patented Technology in Oculoplastic Surgery

*Surgitron* Dual RF  
The Future of Surgery

- Endoscopic Brow Lifts
- Bipolar Hemostasis
- Punctal Occlusion
- Precise Incisions
- Frozen Sections
- Lesion Removal
- Bleph - Ptosis
- Trichiasis
- Pterygia
- DCR

**Oculoplastic Techniques Using High Frequency Radiosurgery**

Video CD Demo By Jay Older, M.D.

**The value of radiosurgery in oculoplastics :**  
"The use of radiofrequency has markedly improved the performance of oculoplastic surgery". With 4.0 MHz high frequency radiosurgery, blepharoplasties and other eyelid procedures can be done with minimal bleeding, minimal swelling, and maximum patient satisfaction. Dr. Older has found that this results in less surgical time and less post-op complications.

For more information:  
(800)835-5355 • [www.ellman.com](http://www.ellman.com) ellman international, inc. NY U.S.A.