

Extragenital and intraanal giant condylomata of Buschke Loewenstein New RF System is an effective treatment alternative



Presented by Miodrag Milojevic, MD, PhD


Presented at the European Academy of Dermatology and Venereology , October, 2011

Provided for educational purposes





prof. dr. Miodrag MILOJEVIĆ
dermato-venereology specialist



dr. Igor JEREMIĆ
gynecology, radiowave dermatosurgery and dermatosthetics
specialist; official educator of the Ellman Co.



Extragenital and intraanal giant condylomata of Buschke Loewenstein New RF System is an effective treatment alternative

HPV (human papilloma virus) is likewise infectious to men and to women.

The incident of HPV infection is increasing on one hand, whereas, on the other hand, the bottom age limit is decreasing every year with highest occurrence between 19 and 24 years of age.

In view of increased occurrence of HPV infection, the prevalence of gigantic condylomata with extragenital localization is observed.

A more frequent localization in perianal, anal and intraanal zone in young patients between the age of 18-25 has also been marked.

Histologically benign change i.e. giant condylomata of BuschkeLoewenstein with its locally destructive growth is manifesting as facultative precancerosis which can progress into planocellular carcinoma.

We have to differentiate giant condylomata of Buschke Loewenstein from malignant tumors as well as from conylomata accuminata.

Histological picture is a key to a differential diagnosis.

Giant condylomata of Buschke Loewenstein is characterized by thickened epidermis with acanthosis, parakeratosis and papillomatosis of epidermis cells. We have a clear spread of epidermis towards dermis , however without invasion of it, with clear vacualization of cytoplasm and koilocytosis of of nucleus which is a typical sign of HPV infection.



What can we say?

Giant condylomata of Buschke Loewenstein is a facultative precancerosis placed in between condylomata accuminata and verrucous carcinoma.

In almost 80% of cases HPV 16 and 18 have been found but in 20% of cases we have a mixed infection with highly and moderately risky viruses (16, 18, 31, 33, 44, 56)

It is often the case that giant condylomata of Busche Loewenstein are combined with precancerosis on PVU and in vulva in women (CIN and VIN I, II, III)



For the same reason, we can encounter precancerosis on the mucosa of the anus in men and penis glans.

Recent research show the presence of HPV 16 and 18 with hypertrophy of prostate and bladder carcinoma in men.

All these data incur high responsibility in diagnostics and adequate choice of treatment of giant condylomata of Buschke Loewenstein.



Genito anal region is highly vascularized and sensitive, and constantly exposed to infections.

A diverse normal bacterial flora is present which in certain conditions may turn into its pathological condition.

Therefore , each form of trauma of higher extent causes intense reaction at genito anal region, accompanied by bleeding, pain, grave post operational condition with pains, infection and unavoidable scarring.

Each forced inflammation is sui generis a precancerosis incident and is one of the most important factors in onco-genesis.

We are aware that the limit is sliding down to more and more younger population.



WHAT IS THE IDEAL THERAPY OF SUCH A PATOLOGY AND DOES IT EXIST?

So far and today, the treatment, removal of changes has been based on radical-mutilating methods in the form of surgical excision and resection, CO₂ lasers, the application of the latter, with no doubt, is limited to smaller lesions.

The degree of recurrence with the two above mentioned methods goes up to 40% and in numbers it is 2 to 8 by patient, which is directly connected to histological picture of Giant condylomata of Buschke Loewenstein.

It is exactly the reason for a radical approach which normally brings along a certain degree of risk, complications, invalidity and other undesirable side effects.

It is especially difficult to have a radical approach in the region of anus and intra anus with young girls who have not given birth to a child or pregnant women.

CONCLUSION

We need a technology and work technique which is not radical and not mutilating, but which, at the same time makes it possible to completely remove the lesion, preferably, in local anesthesia, which will induce little bleeding, if any, and minimum destruction of surrounding healthy lateral tissue, with speedy recovery without complications and subsequent scarring.

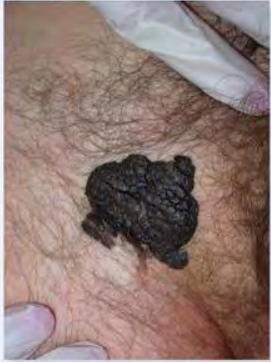Such a technology has to be safe for young persons and pregnant women.

Recurrence has to be below 3% and if they occur, repetition rate should not be higher than three times.

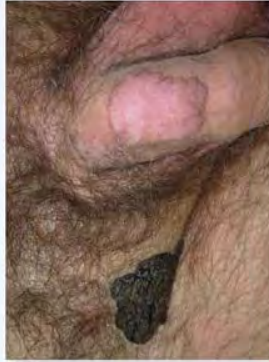

4MHZ RADIO WAVE FREQUENCY TECHNOLOGY COUPLED WITH SPECIAL PROCEDURE TECHNIQUE GUARANTEES THE BEST THERAPEUTIC RESULTS IN TREATMENT OF GIANT CONDYLOMATA OF BUSCHE LOEWNSTEIN.

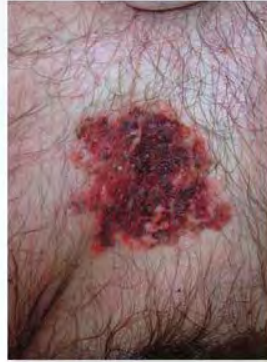Over 100 patients of both sexes, aged 19-52 (mean age 37) with peculiar extragenital and intraanal localization of giant condylomata of Buschke Lowenstein have been successfully treated with an RF system (4 MHz-120 watt)



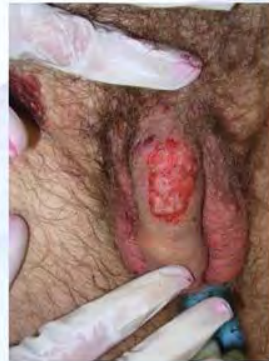before



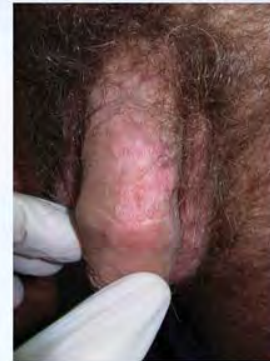before



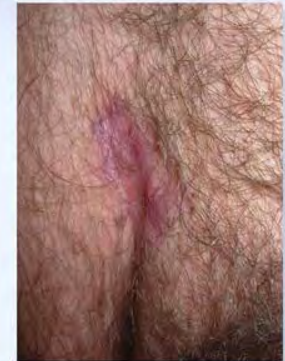immediately after



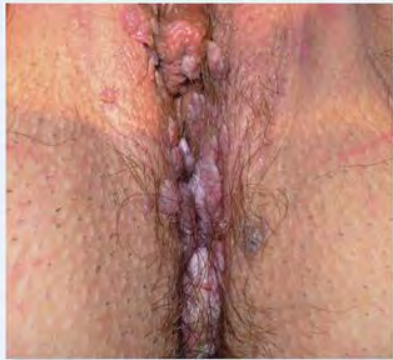immediately after



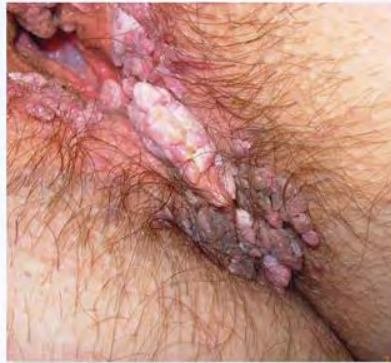after 3 months



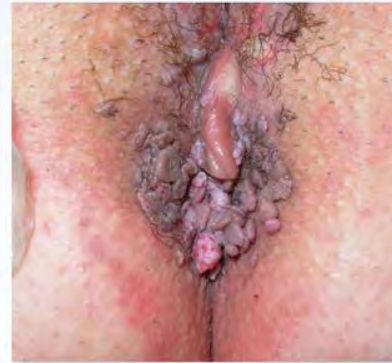after 3 months



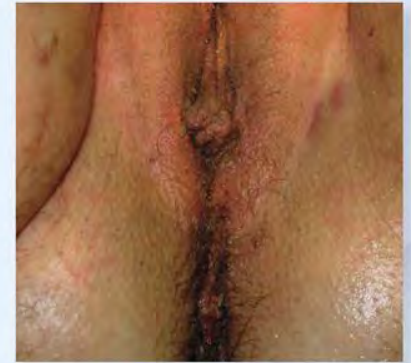before



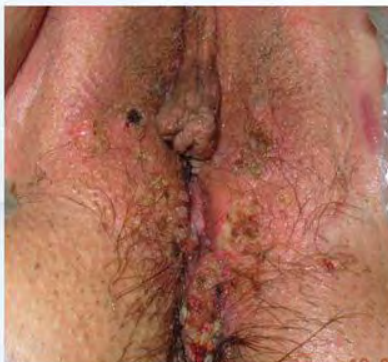before



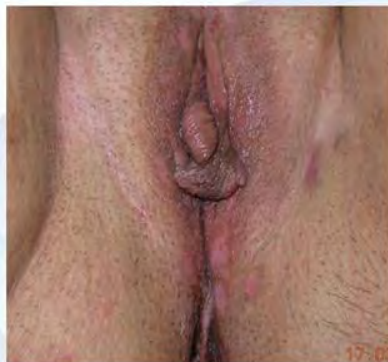before



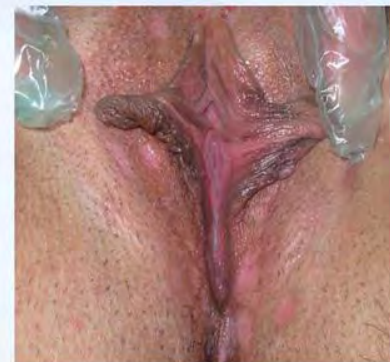immediately after



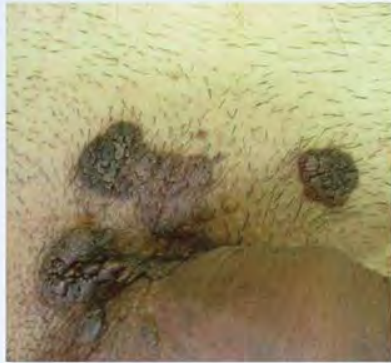immediately after



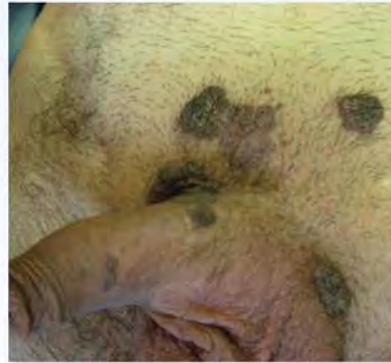after 3 months



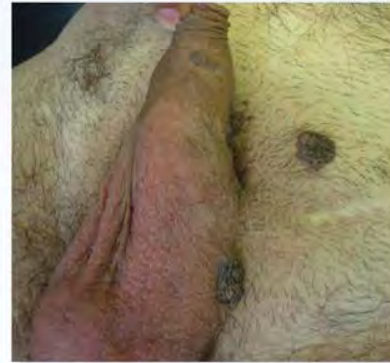after 3 months



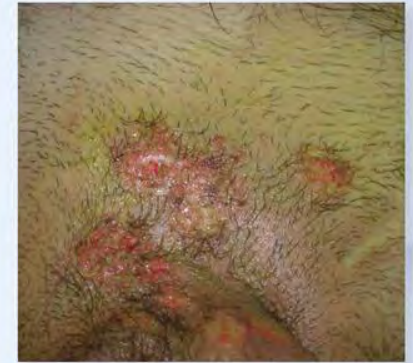before



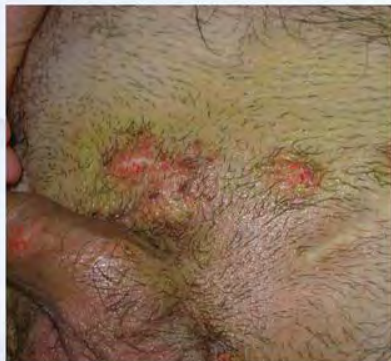before



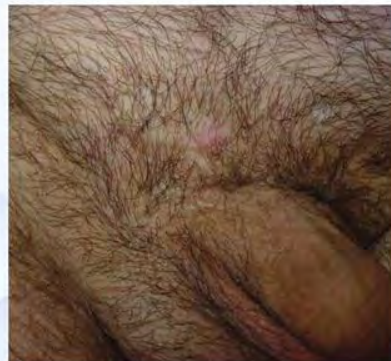before



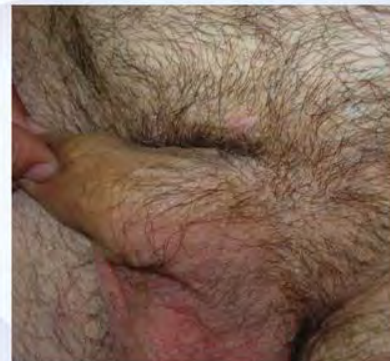immediately after



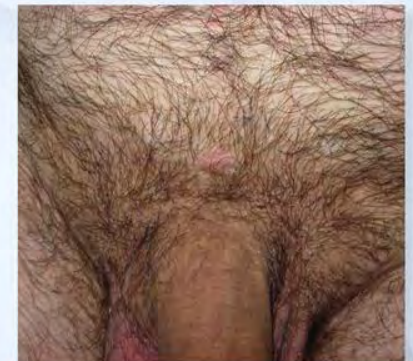immediately after



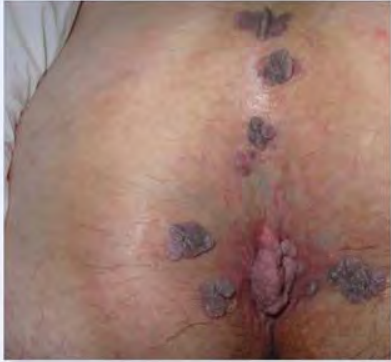after 4 months



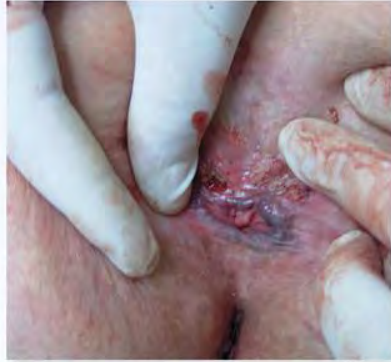after 4 months



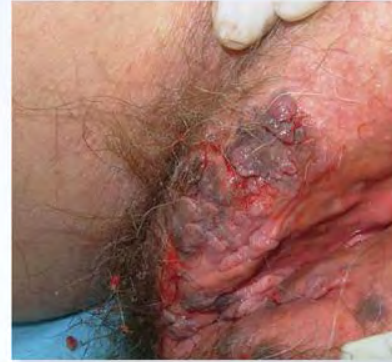after 4 months



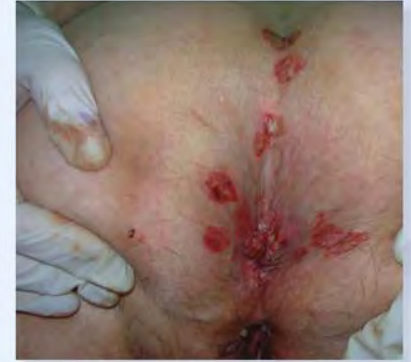before



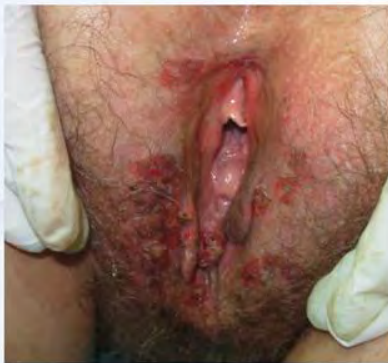before



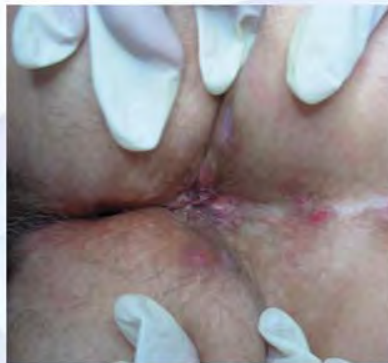before



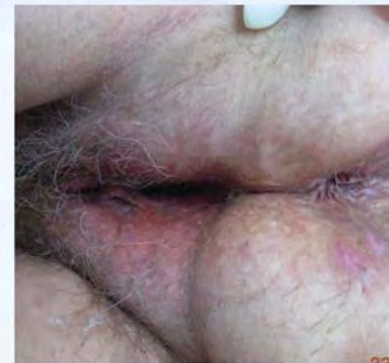
immediately after



immediately after

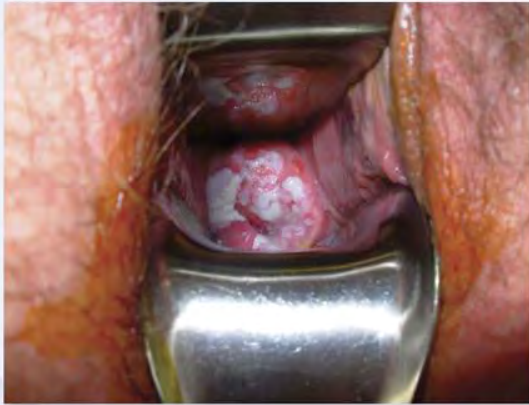


after 3 months

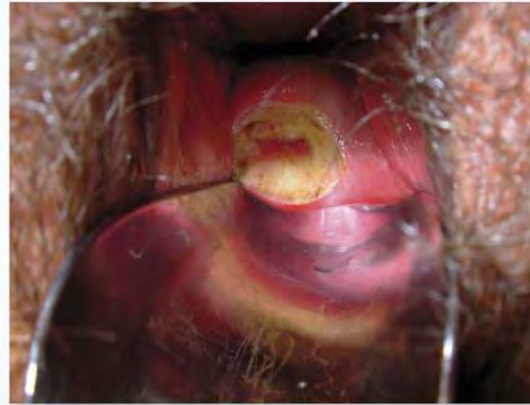

after 3 months

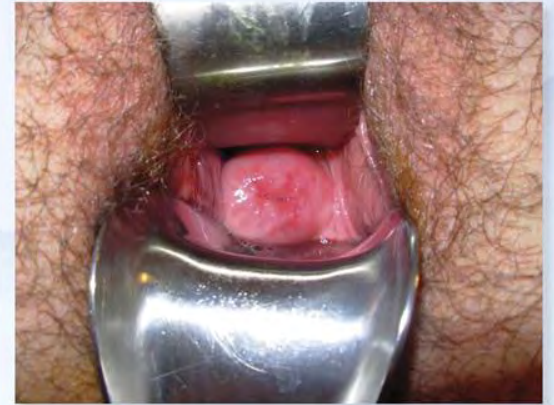Radiowave LOOP excision



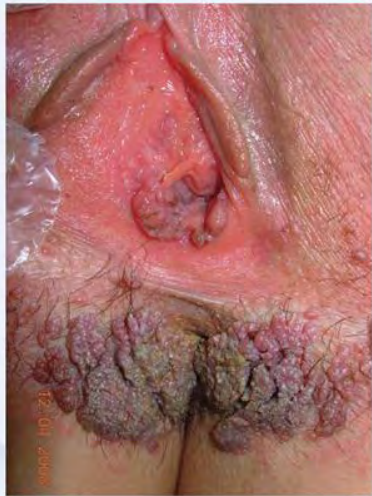before



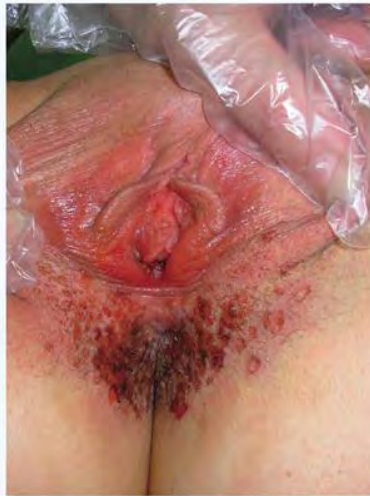after



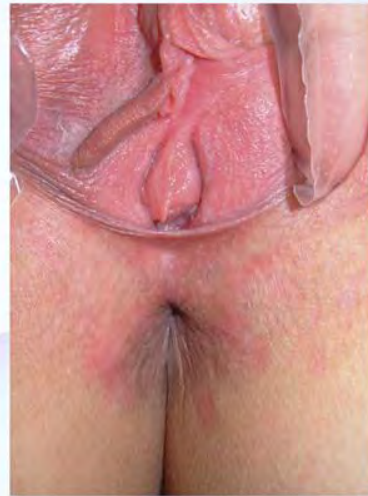after 2 months



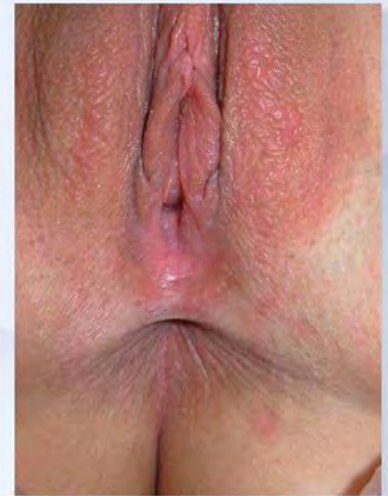
before



immediately after

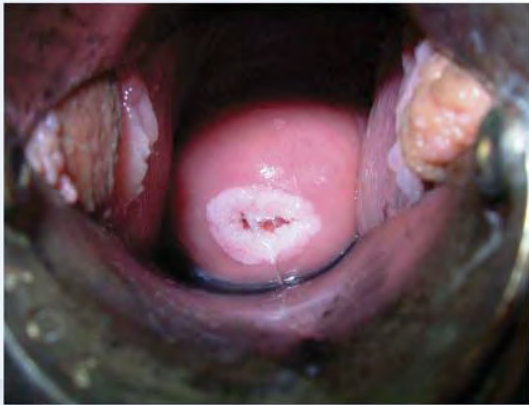

after 3 months

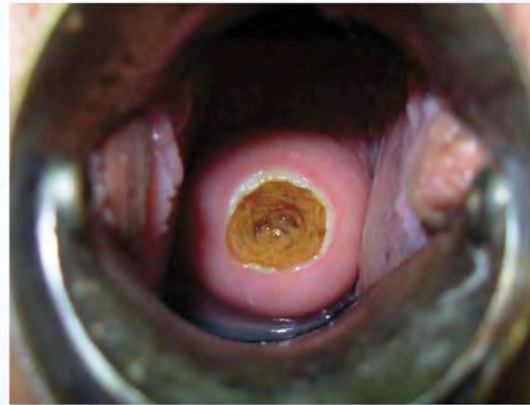

after 3 months

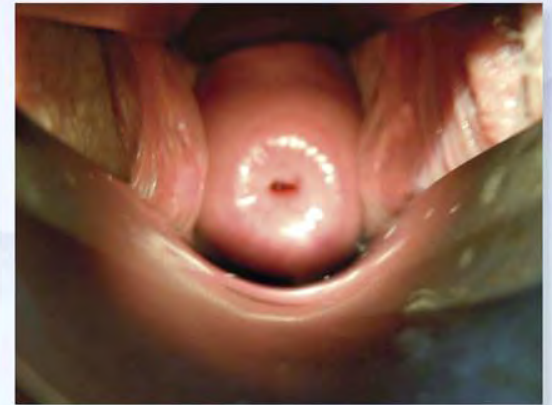Radiowave LOOP excision



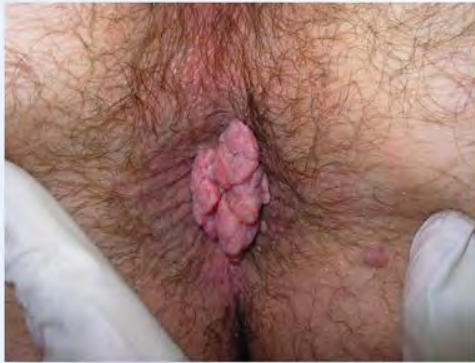before



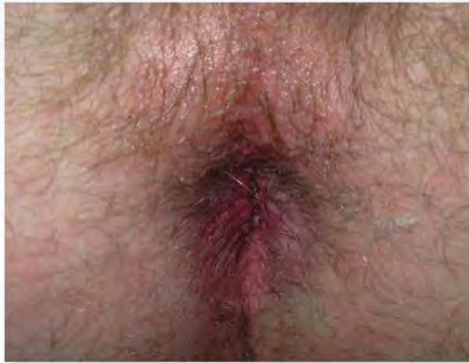after



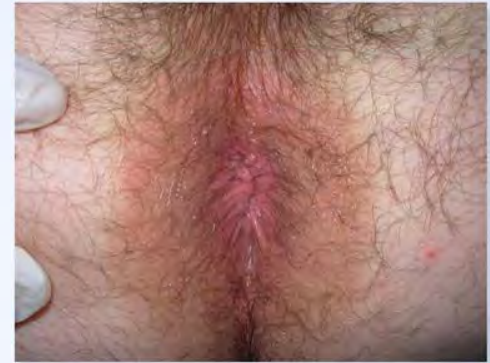after 2 months



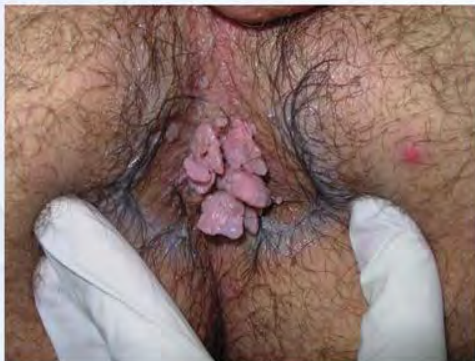before



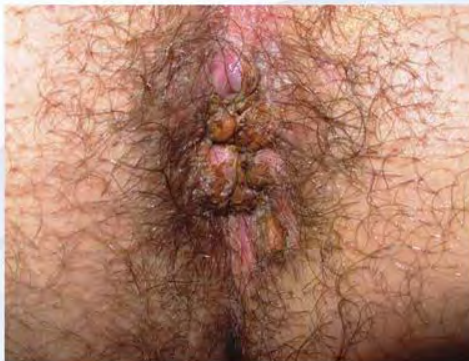immediately after



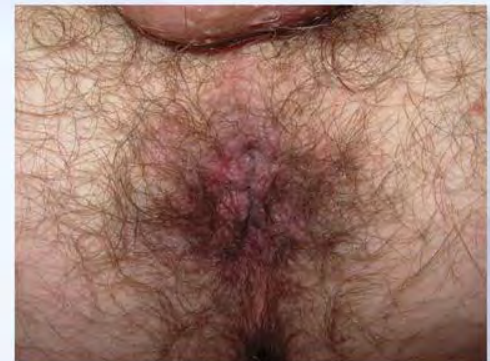after 3 months



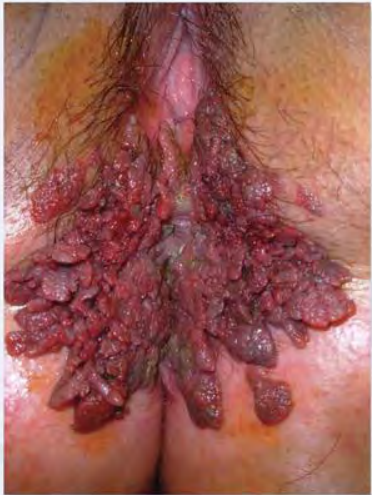before



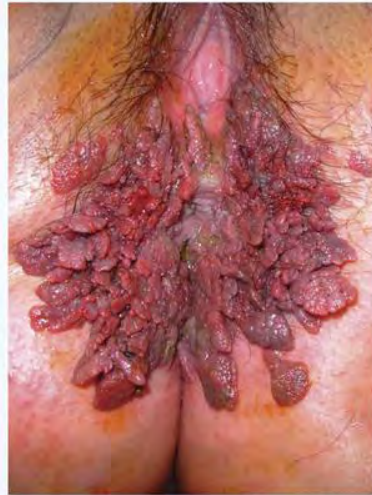immediately after



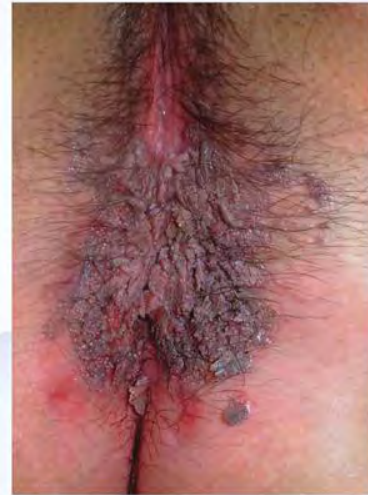after 3 months



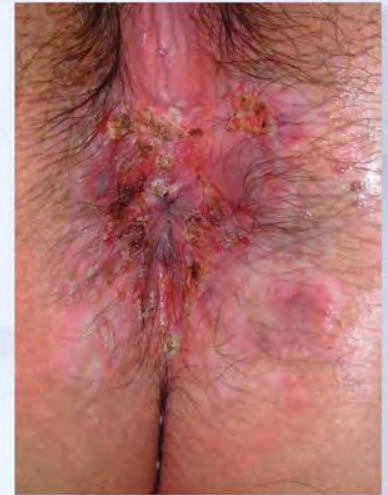before



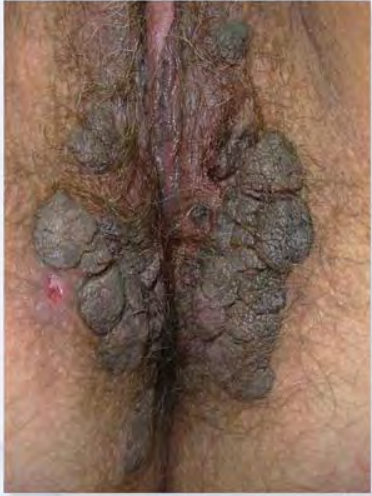before



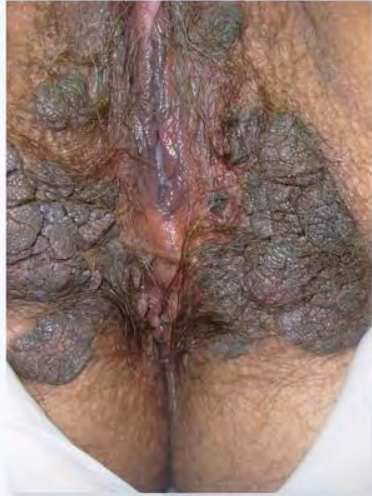after first intervention



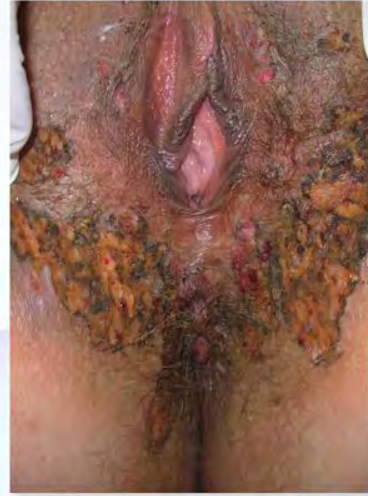after second intervention



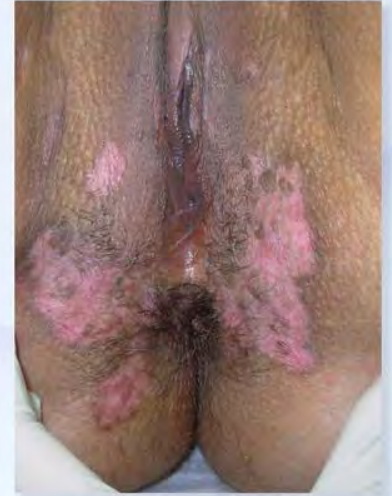before



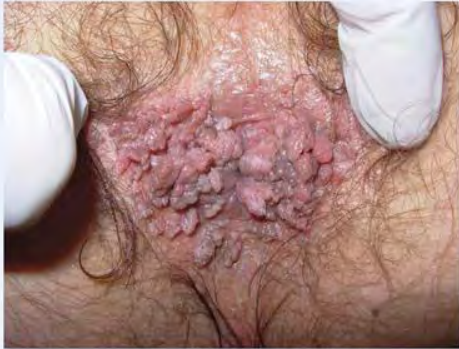before



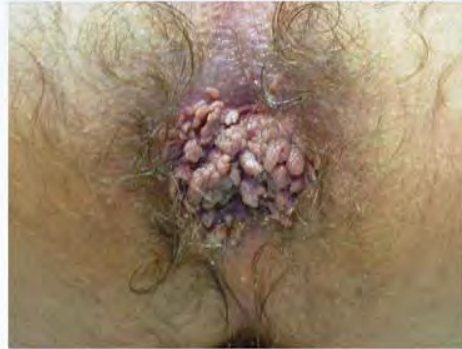after



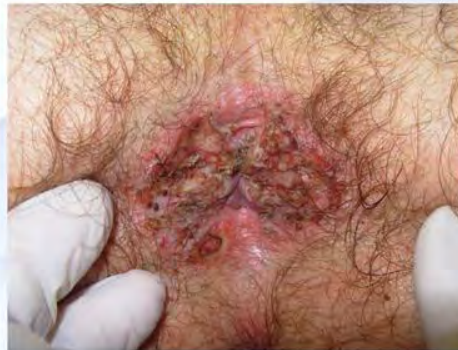after 2 months



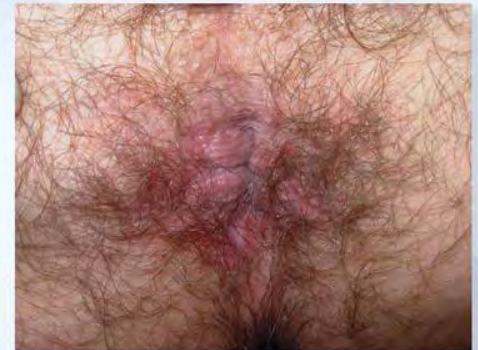before



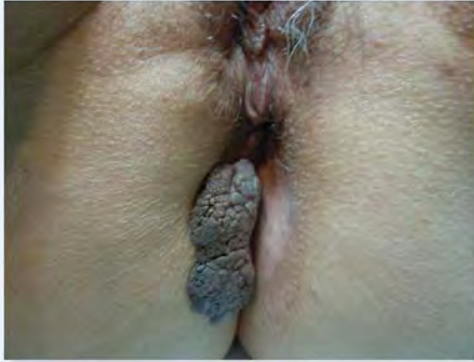before



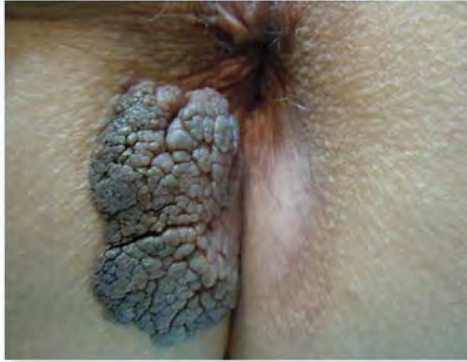immediately after



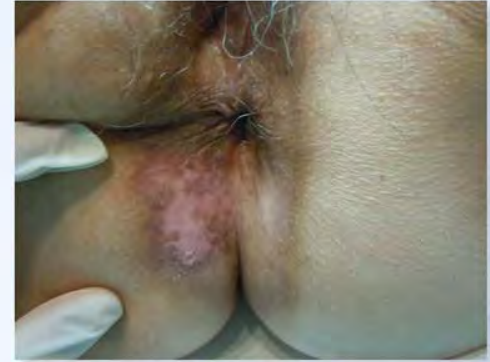after 6 months



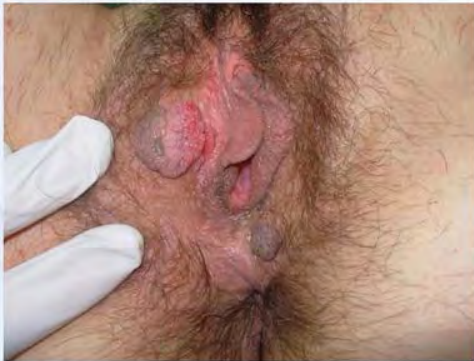before



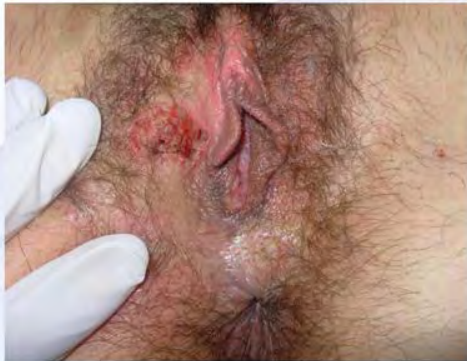before



after 3 months



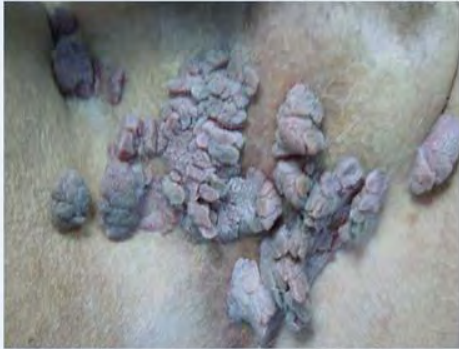before



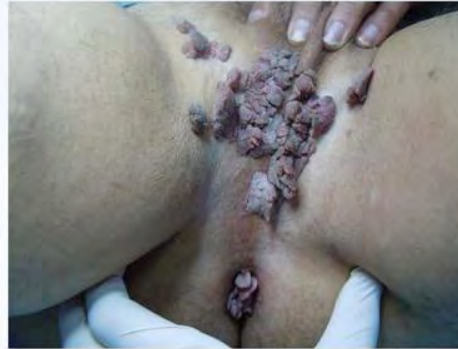immediately after



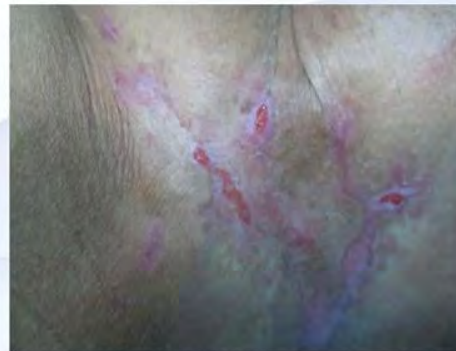after 2 months



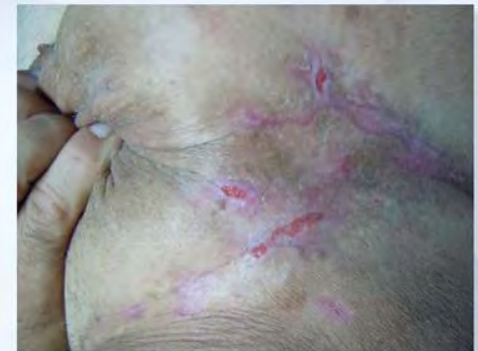before



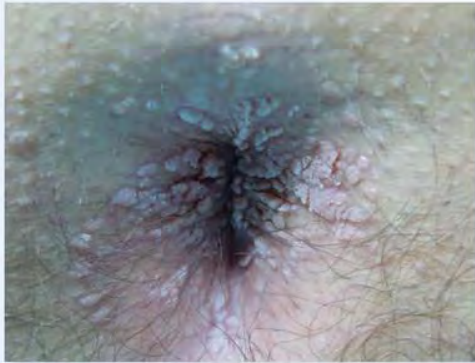before



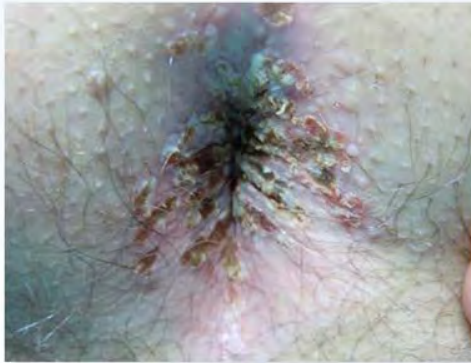after 1 month



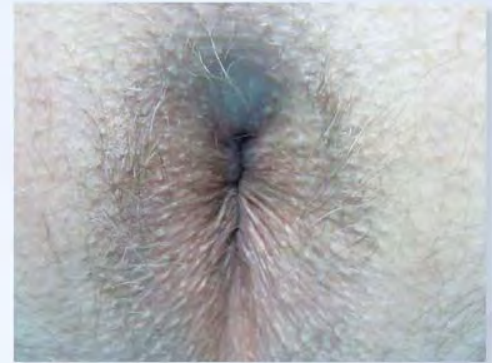after 1 month



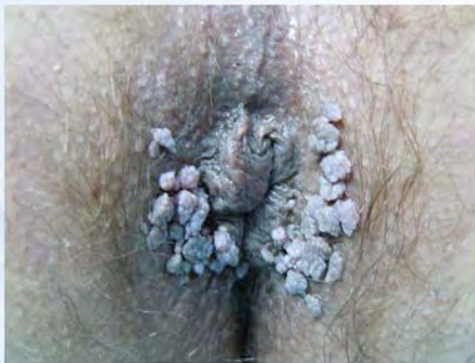before



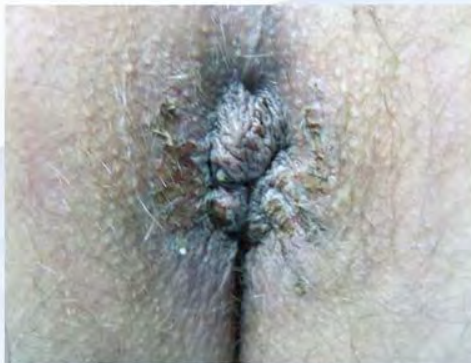immediately after



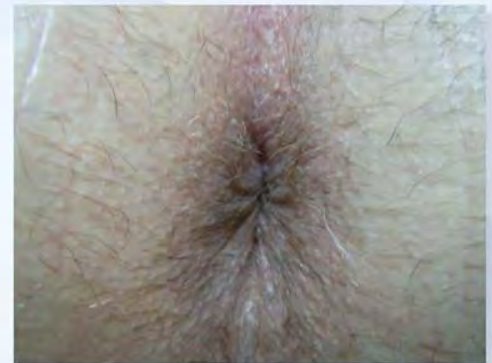after 6 months



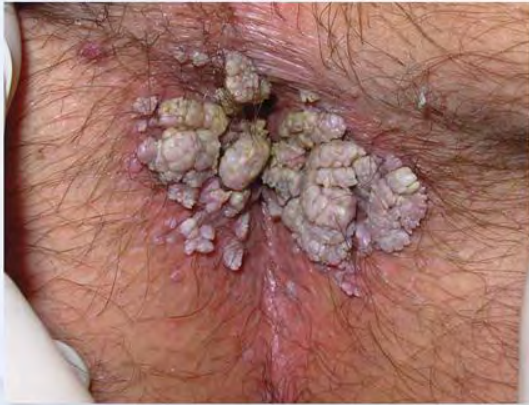before



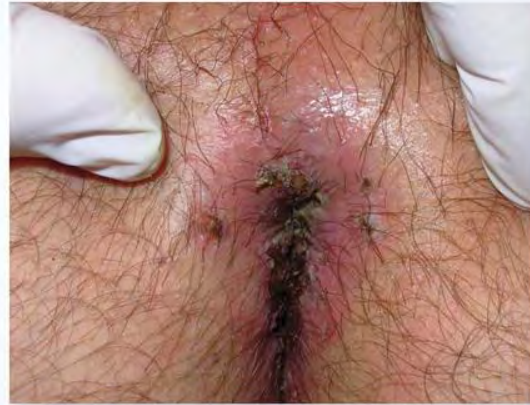immediately after



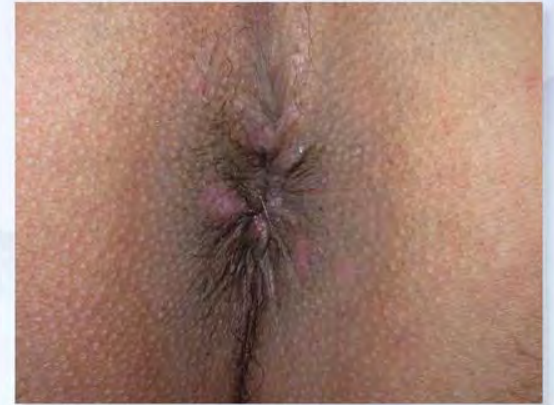after 6 months



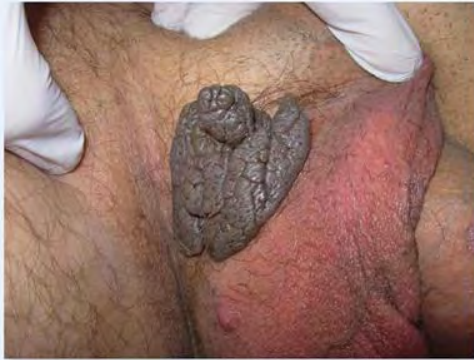before



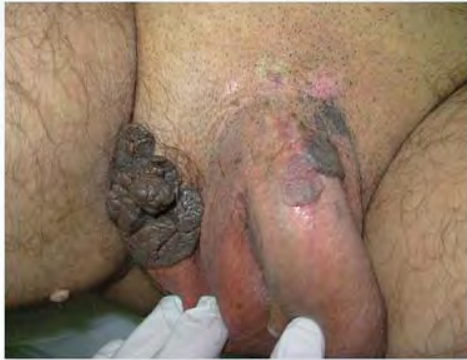immediately after



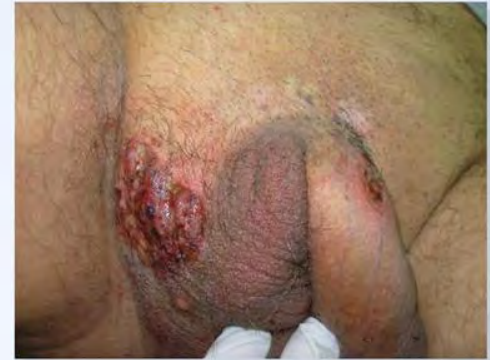after 2 months



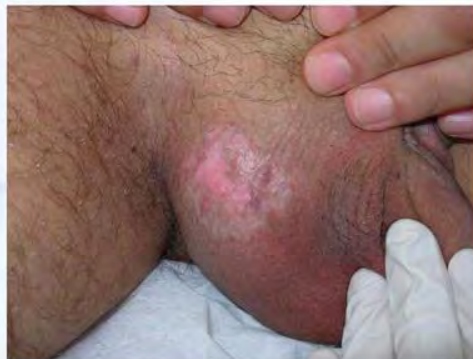before



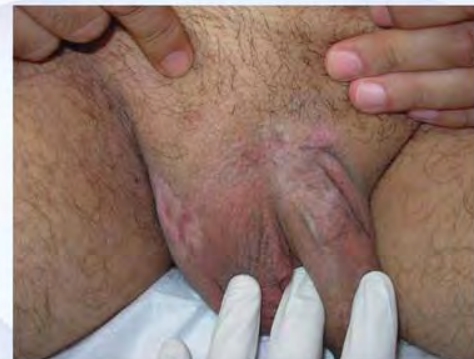before



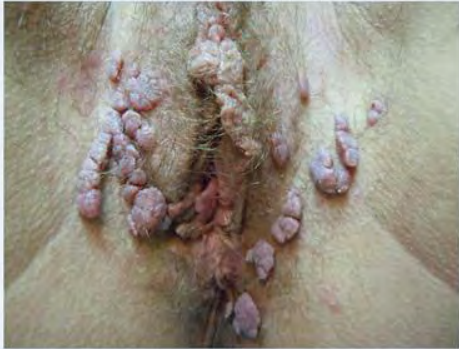immediately after



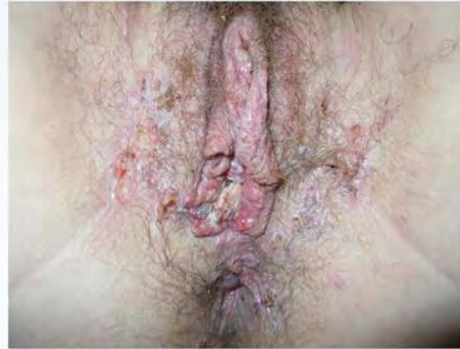after 3 months



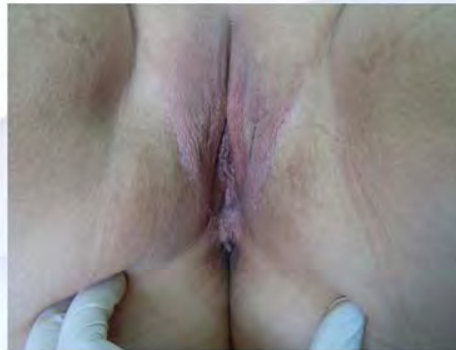after 3 months



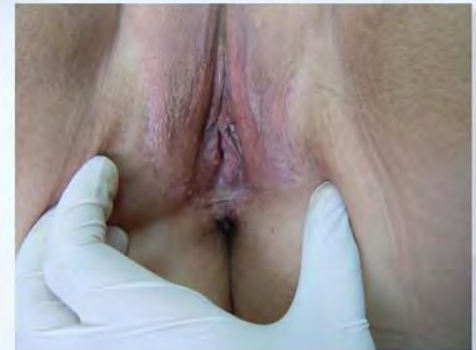before



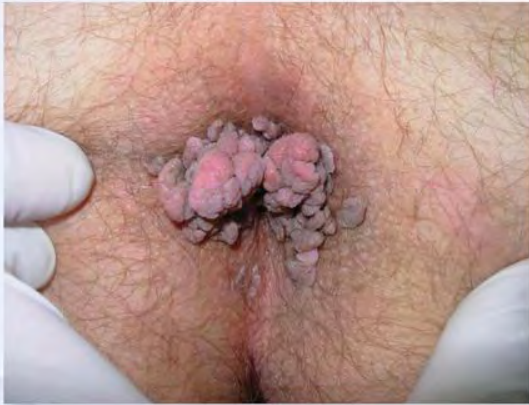immediately after



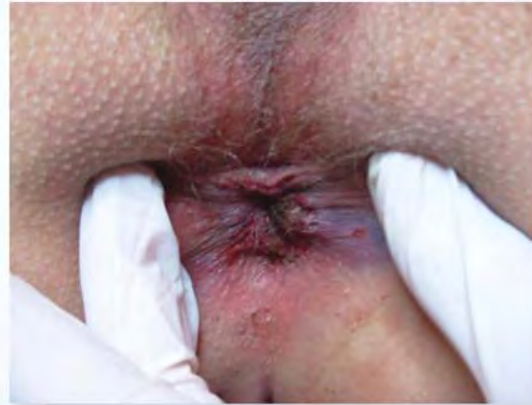after 6 months



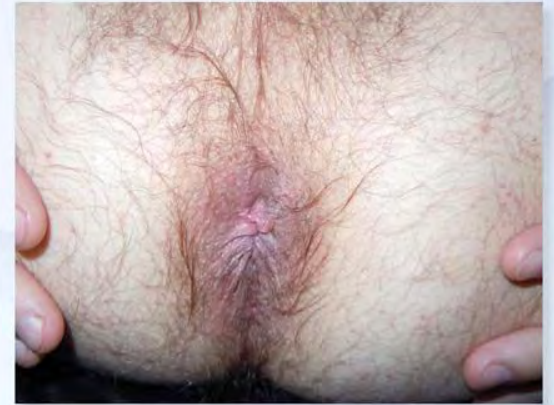after 6 months



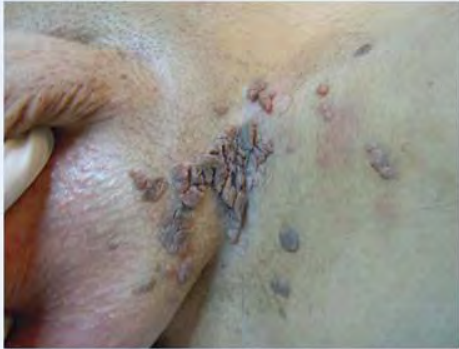before



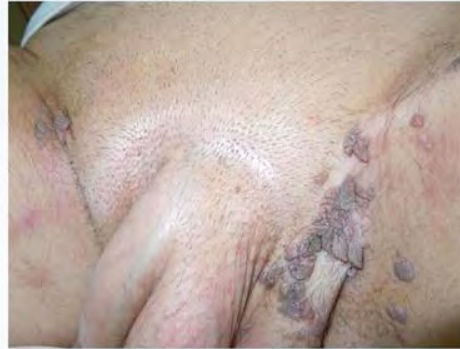immediately after



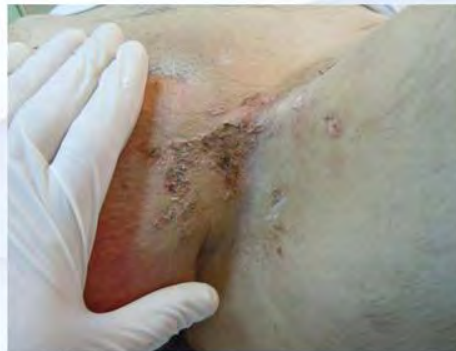after 6 months



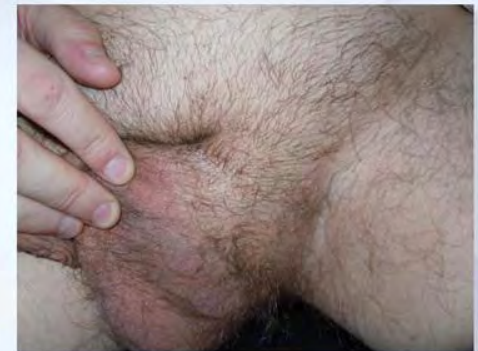before



before



immediately after



after 6 months

With the application of radio wave technology and special technique of work procedure of Dr Jeremic, we have obtained outstanding therapeutic results.

With over 90% of cases, there has been no recurrence of changes whatsoever.

In about 7% of cases there has been only one occurrence with minimum recurrence of changes on borders of previous changes, most often in the region of intraanus and perianus.

In less than 3% of cases, patients came 2 to 4 times for re-intervention, mostly with imunocompetent patients.

There are no scars in 100% cases, neither sexual dysfunction.

WHICH POSTULATES SHALL WE FOLLOW IN OUR WORK, IN ORDER TO ACHIEVE THE AFOREMENTIONED RESULTS?

- 1. We need to employ Ellman radio frequency technology with attachments which incur damage of lateral tissue less than 10 microns , having at the same time full control of work and simultaneous coagulation without crush effect (multiple different attachments for excision and radio wave vaporization.**
- 2. It is also crucial to have as little as possible of bleeding in the course of the intervention, which is one of the preconditions for recurrence. It is necessary to remove layer after layer, with so called shaving technique, followed by radio wave frequency vaporization, which stops the bleeding, per layer.**

3. Full control of work procedure and intervention area, with removal of changes as far as the dermis.

Digging into dermis is out of question, since recovery will be extremely heavy, accompanied by inflammation and mutilation, with frequent recurrence.

4. Under no circumstances, there has to be no crush effect as with CO₂ laser, further on, no show of necrosis on treated areas, fulguration of healthy tissue, since all of these, are preconditions for inflammation, mutilations and recurrence.

What are the benefits of this technique?

- 1. Possibility of intervention in local anesthesia**
- 2. Duration from 5-30 minutes depending on the gravity of clinical picture**
- 3. Achieving of full recovery in 3-5 weeks**
- 4. Minimum percentage of recurrence**
- 5. No scarring, sexual dysfunction. Safe when employed in pregnancy.**
- 6. Reintegration of the patient in normal daily activities.**
- 7. Sexual intercourse is possible 6 weeks upon intervention**

If, after 6 months following the intervention a patient discharged with normal status reports a recurrence of HPV, it is a case of new infection, not a recurrence.

THE CHOICE OF ADEQUATE TECHNOLOGY AND TECHNIQUE IS THE KEY OF THERAPEUTIC SUCCESS, REGARDLESS OF THE GRAVITY OF CLINICAL PICTURE.

This material is intended to provide general information, including opinions and recommendations, contained herein for educational purposes only. Such information is not intended to be a substitute for professional medical advice, diagnosis or treatment. The material is not intended to direct clinical care in any specific circumstance. The judgment regarding a particular clinical procedure or treatment plan must be made by a qualified physician in light of the clinical data presented by the patient and the treatment options available.

Please review the Instructions for Use for a complete listing of indications, contraindications, warnings, precautions and potential adverse events prior to using these devices. Federal Law (USA) restricts these devices to sale, distribution, or use by or on the order of a physician.

As a manufacturer of wrinkle treatment systems, Ellman, Inc. has an interest, commitment and responsibility to stay current with the latest advancements and achievements in this area.